

Case study: Basal cell carcinoma of the temporal region

Enluxtra® Self-Adaptive Wound Dressing Clinical Results

Patient:

A 62-year-old male presented with a nonhealing soft tissue radionecrosis wound of the left facial and temporal region following severe radiation damage post basal cell carcinoma. Patient's medical history also included hypertension and stage II chronic kidney disease.

Wound Description:

Continual drainage from the exposed frontal sinus was contaminating and causing inflammation to the surrounding soft tissue, prolonging wound healing process. Wound healing was further complicated by desiccation of wound edges and non-exudative portions of the wound, as well as formation of necrotic tissue and biofilms.

Initial Wound Treatment:

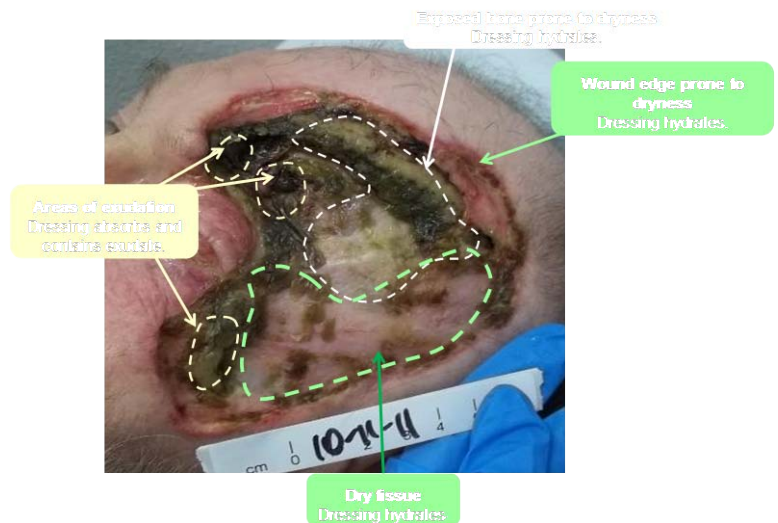
A range of absorbent dressings, including hydrocellular and self-adherent polyurethane foams, were tried in the wound and were unsuccessful in controlling drainage of the sinus fluid and necrotic tissue formation. The wound required weekly debridements to remove necrotic tissue, which was increasing the wound size and traumatizing the wound edges, exposed bone, and the fragile thin tissue layer over the brain. Brain pulsating movement could be observed in the center of the wound. Continual debriding of this fragile area due to drainage deterred the healing process.

Application of Enluxtra:

Ten weeks after the patient initially presented to our clinic, the wound measured 10.0 x 13.0 x 1.0 cm with exposed bone (Fig. A). Debridement was performed, and Enluxtra was placed on the wound, overlapping 2 to 3 cm onto intact skin, and secured with non-woven cotton tape at the first dressing change. On follow-up visit, additional folded gauze was added to the outer Enluxtra dressing and cotton tape to ensure wound bed contact with the Enluxtra and aid drainage absorption and biofilm elimination.

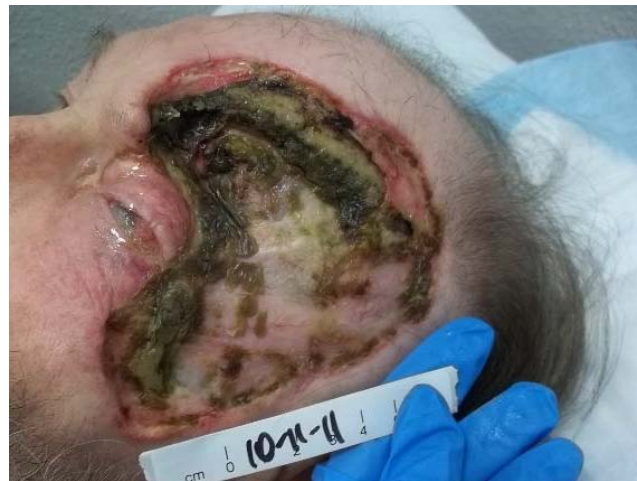

Fig. A. Chronic soft tissue radionecrosis wound prior to use of Enluxtra is filled with necrotic tissue and contaminated with sinus fluid



Wound Progression with Enluxtra:

Two weeks following initial placement of Enluxtra, the wound displayed marked signs of improvement. Drainage was controlled and isolated within the dressing, and healthy pink tissue was present in the wound bed and on wound edges (Fig. B).

Exudate containment and maintenance of correct moisture balance throughout the entire wound led to a drastic reduction in sharp debridements and associated trauma to the exposed bone and healing tissues. The layer of tissue covering brain tissue continuously retained its moisture, and appeared strengthened within one month of Enluxtra use (Fig. C).

After 3 months of Enluxtra, wound size was decreased, sinus fluid remained contained, and granulation buds were present throughout the wound bed (Fig. D).

User Experience:

The patient reported increased comfort with the dressing, particularly with respect to painless dressing removal, leak-free dressing and decreased debridement frequency. Other dressings applied prior to Enluxtra leaked drainage into the eye and inner ear, requiring frequent debridement and use of antibiotic eye drops for inflammation and irritation.

Clinical Outcomes/Conclusion:

All areas of this complex soft tissue radionecrosis wound responded positively underneath the Enluxtra dressing throughout the 12-week application period. Improved moisture balance and considerably reduced necrotic tissue and biofilm formation were observed with application of Enluxtra, compared to previous dressings used in this wound. Enluxtra appeared to assist in autolytic debridement, which greatly decreased the need for sharp debridement and allowed the underlying healthy tissue to consistently remain on a positive wound-healing trajectory.

Reference:

Vicki Fischenich, GNP-BC
Dr. Randall Wolcott
Southwest Regional Wound Care Center
Lubbock, TX

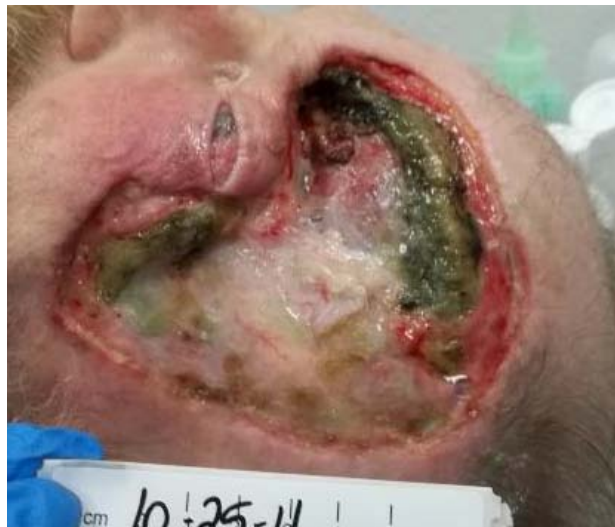

Fig. B. Two weeks following initial use of Enluxtra, sinus drainage is controlled and pink granulation buds are present in the wound bed

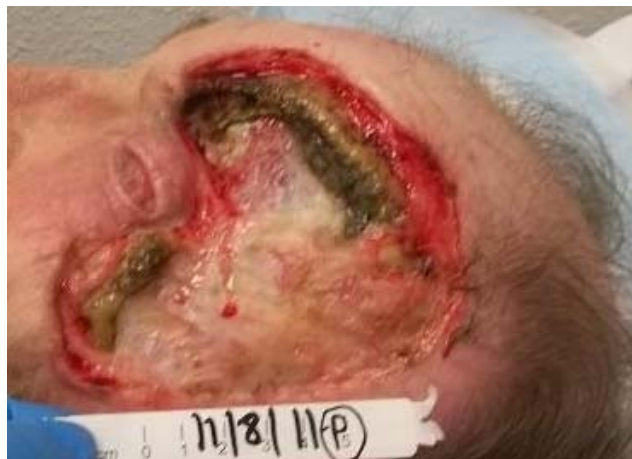

Fig.C. After 1 month's use of Enluxtra, the need for debridement was drastically reduced and the thin tissue over the brain remained optimally moist and granulated

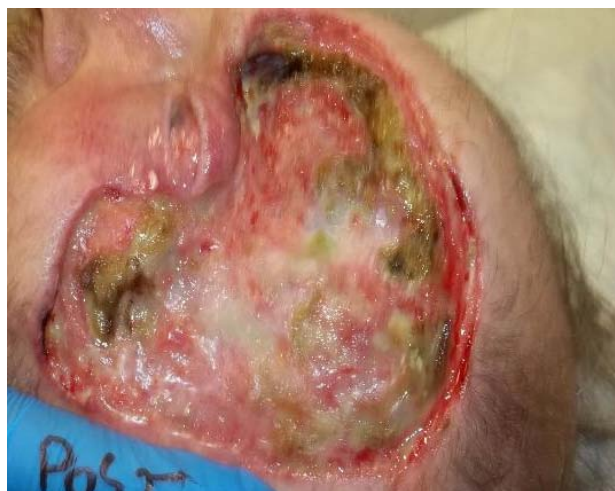

Fig.D. After 3 months of Enluxtra, wound edges appear healthy, and all dimensions are smaller