Case study 6: Deep tissue injury, left hip

Enluxtra™ Self-Adaptive Wound Dressing Clinical Results

Patient:

The patient is an 78-year-old female, non-ambulatory. Co-morbidities: peripheral arterial disease, history of stents to right leg, diabetes, hypertension, right-side below knee amputation.

Wound and previous treatment:

Patient is house-bound, with limited mobility. Initial deep tissue injury (DTI) progressed to unstageable due to insufficient offloading of the wound site. The depth of DTI was unknown as it was obscured by a non-vital skin over the DTI site.

Enluxtra treatment:

Enluxtra dressing treatment started in May, 2016 with dressing changes every 2-3 days. As the result of natural autolytic debridement of the non-vital skin over the DTI site, a black mass of necrotic tissue was revealed. On June 4 the patient has been referred to the PCP for wound assessment. A decision was made to perform surgical debridement to remove the necrotic tissue from the wound, re-assess the wound for the depth of DTI, and expedite healing progress. The procedure was done on June 9 and it revealed the depth and extent of the wound. The wound was categorized as stage IV.

At the post-debridement follow-up the PCP made a decision not to proceed with the initially planned NPWT but instead to continue with Enluxtra dressings in combination with gauze wound filler to wick the exudate from the deep wound bed. Enluxtra applications continued with gradually reduced change frequency until full wound closure in 12 weeks.

Conclusions and clinical outcome:

Usually, the treatment of this challenging wound could follow different scenarios and involve numerous wound care products and expensive therapies. However, due to Enluxtra's versatility, clinicians were able to use just this product throughout the entire healing trajectory: from the beginning as an unstageable DTI to post-debridement open wound with undermining to complete closure. Enluxtra dressing provided appropriate care at each of these stages, removing slough, protecting periwound skin and supporting healing.

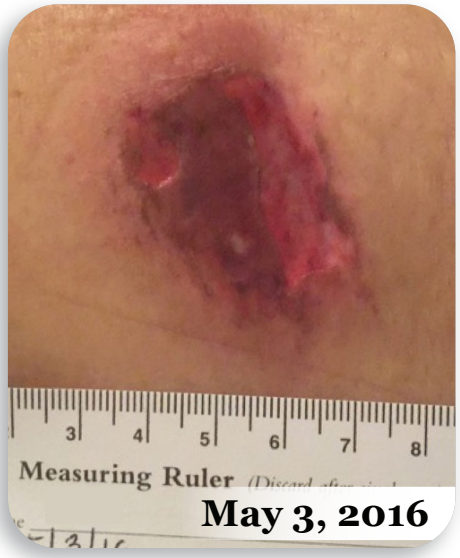

May 3, 2016


June 4, 2016


June 9, 2016


July 14, 2016


August 18, 2016


September 15, 2016

Reference: Marilen Cabrera, RN Home Health Care Chicago, MN